coatings

MDPI

Article

The Assessment of the Usefulness of Platelet-rich Fibrin in the Healing Process Bone Resorption

Iwona Niedzielska, Daniel Ciapiński, Michał Bąk* and Damian Niedzielski

Department of Cranio-Maxillo-Facial Surgery, Medical University of Silesia in Katowice, ul. Francuska 20-24, 40-027 Katowice, Poland; szczekowo-twarzowa@sum.edu.pl

* Correspondence: mbak@sum.edu.pl;

Abstract: The main subject of the research was the use of PRF in dental surgery aimed at preventing changes in alveolar height and width after tooth extraction. Due to the large growth factor content, it seems to be particularly useful in bone loss management starting from the simplest loss occurring after tooth extraction through loss resulting from tooth resection ending with loss caused by large bone cysts. The study was performed in 50 patients. The extraction of two maxillary or mandibular homonymous teeth was carried out in each patient, where PRF was placed in one alveolus while the other alveolus was left empty. Then the alveoli were surgically managed with a split flap technique. On the day of extraction, on the 10 day and after 6 months, the alveolar process was measured, soft tissues healing was assessed, and imaging examinations were analyzed. It was proved that the healing of soft tissues of the alveoli in which platelet-rich fibrin was used was better compared to the alveoli where PRF was not applied. In the group of the alveoli with platelet-rich fibrin also better bone remodeling occurred and after 6 months from surgery, the newly formed bone had higher optical density in volumetric tomography (CBCT). Moreover, faster wound healing and the mineralization of the newly formed bone causes the reduced atrophy of the alveolar process in the site of the extracted tooth, which was proved in this study.

Keywords: platelet-rich fibrin; guided bone regeneration; bone preservation; cone beam computed tomography

Citation: Niedzielska, I.; Ciapiński, D.; Bąk, M.; Niedzielski, D. The Assessment of the Usefulness of Platelet-rich Fibrin in the Healing Process Bone Resorption. *Coatings* **2022**, *12*, x. https://doi.org/10.3390/xxxxx

Academic Editor(s):

Received: date
Accepted: date
Published: date

Publisher's Note: MDPI stays neutral with regard to jurisdictional claims in published maps and institutional affiliations.

Copyright: © 2022 by the authors. Submitted for possible open access publication under the terms and conditions of the Creative Commons Attribution (CC BY) license (http://creativecommons.org/licenses/by/4.0/).

1. Introduction

At present implantological treatment has become a popular way of tooth replacement. However, to be successful and to satisfy high white and red aesthetics standards, it requires the appropriate amount of bone and keratinized gingiva. Appropriate alveolar process management after tooth loss becomes important in order not to allow the reduction of the alveolar process volume to occur and so that the procedures are as inexpensive and non-invasive for the patient as possible. Today atraumatic tooth extraction using periotomes is the gold standard, but it does not prevent the loss of the alveolar process volume entirely. The remodeling and healing of the post-extraction alveolus involves the reduction of width and height of the post-extraction alveolus already in the first 8 days [1,2]. This physiological bone atrophy amounts on average to 25-30% [3] and some authors report that in the period of 2-3 years atrophy amounting to 40-60% of the volume of the alveolar process occurs [4,5]. The healing of the alveolus is the outcome of resorption process and neo-osteogenesis which take place from the outside and the inside of the alveolus and have an impact on the future shape and appearance of the alveolar process [6]. Araujo and Lindhe's research shows that the healing of the alveolus entails mainly bone atrophy from the side of the oral vestibule and this alveolus is always below the level of adjacent teeth. Cells responsible for bone formation are, in this case, not active enough or there are too few of them [7].

The best material for bone loss regeneration is the autogenous bone obtained both from maxillary and mandibular bones as well as from outside of the oral cavity [8]. Only the autogenous bone and some allogenic materials have osteoinductive abilities. The remaining materials act osteoconductively as thrombus stabilizer or construction for infiltrating cells [9,10].

In 2001 dr. Joseph Choukroun et al. from Nice made an effective attempt to obtain platelet-rich fibrin (PRF) from whole blood [11]. This method is a simple and cheap procedure based on natural biological processes. One of the major advantages of this method is the lack of necessity of using coagulation factors, bovine thrombin, calcium chloride or gelling agents and it is not harmful for the organism [12]. PRF contains numerous blood platelets as well as cytokines which are released from the thrombus. However, the most important part is played by platelet-rich fibrin matrix which is responsible for actual therapeutic potential [13–17]. Cytokines themselves quickly lose their activity but they have much greater significance in combination with fibrin matrix. PRF matrix combined with cytokines demonstrates longer activity unlike other fibrin glues. The research from 2005 and the one conducted in 2011 proved that living platelets contained in platelet-rich fibrin [PRF] were able to release growth factors, i.e. platelet-derived growth factor - PDGF, vascular endothelial growth factor - VEGF, transforming growth factor - EGF in the same concentration for the period of 7 days [11,18].

Platelet-rich fibrin has found its application in dental and maxillo-facial surgery, plastic surgery, otolaryngology, and chronic wound treatment [11,19–21]. Publications of the last few years concerning platelet-rich fibrin include practically all the fields of dentistry. It has been used, among other things, for treating the perforation of the bottom of the pulp cavity in combination with MTA, multiple gingival recessions or in periodontal diseases [22–27].

The aim of the study was to answer the 3 principial questions:

1. Can the insertion of the PRF to the post-extraction socket enhance soft tissue and bone healing?
2. How the insertion of the PRF to the post-extraction socket affect the CBCT measured Grayscale Values?
3. How the insertion of the PRF to the post-extraction socket affects the post-extraction bone loss?

2. Materials and Methods

A randomized study was performed in a group of patients reporting to the University Hospital Outpatient Clinic of Maxillofacial Surgery in Katowice in the years 2011/2012 for the purpose of the sanitation of the oral cavity. The study was approved by the bioethics committee of Medical University of Silesia (protocol KNW/0022/KB1/97/II/10/11).

Based on a medical history, physical examination and additional examinations (panoramic radiographs and adjacent x-rays) patients meeting the following criteria were qualified for further study:

Inclusion criteria for the study:

1. The presence of two maxillary or mandibular homonymous teeth qualified for extraction (teeth with pulp gangrene with or without periapical lesions with a diameter of no more than 1 cm which cannot be treated conservatively due to considerable damage to the crowns of the teeth, teeth after the failures and complications of endodontic treatment with considerable damage to the tooth crown
2. The bony walls of the alveolus intact during extraction and preserved adjacent teeth
3. The extraction of two teeth in the same patient comparable with respect to surgical procedure duration
4. The lack of local and general contraindications for tooth extraction
5. Patients without systemic diseases

Patients with metabolic diseases, active smokers, chronic alcoholics as well as patients after radiotherapy and chemotherapy within the head and neck area and patients with chronic periodontal diseases were excluded from the study.

2.1. Surgical Procedure

The minimally invasive extractions of two homonymous teeth were carried out under local anesthesia with 2% lidocaine with noradrenaline. After performing anesthesia, venous blood was collected from the cubital fossa in the amount of 18 ml for the incisors, canines, and premolars' alveoli as well as 27 ml for the molars' alveoli. The blood was collected in vacuum test tubes of a capacity of 9 ml and next it was centrifuged using the EBA-20 centrifuge at 2700 rpm in accordance with the protocol described in 2001 by dr. Joseph Choukroun.

The lack of anticoagulant allows to activate the majority of platelets and triggers the coagulation cascade in a simple manner. The whole process of slow coagulation and centrifuging results in the formation of the fibrin clot containing platelets located in the middle part of the test tube. Platelet-rich fibrin (PRF) is located between the mass of red blood cells, red base corpuscles (RBC) at the bottom and platelet-poor plasma (PPP) at the top [20,28] (Figure 1).



Figure 1. Vacuum tube after centrifugation (3 layers visible – the middle is the PRF).

After centrifuging, the PRF clot was removed from the test tube (Figure 2A), separated from red blood cells (Figure 2B) and in such a form it was inserted in one of the alveoli after homonymous teeth extraction. The study was performed according to the outline included in Table 1.



(**a**) (**b**)

Figure 2. Centrifuged PRF: (**a**) removing the PRF from test tube; (**b**) PRF separated from red blood cells.

Table 1. Study outline.

Teeth extraction day	10th day after extraction	6 months after extraction
- alveolar width and height measurement with Koehler 6401 caliper	-ARSTH scoring -CBCT and alveolus measurements	- alveolar width and height measurement with Koehler 6401 caliper - CBCT and alveolus Measurements - Grayscale Value measurement on the base of CBCT

After extracting teeth by means of the 3182 Kohler periodontal probe, the presence of the bony walls of the alveoli after extraction was checked and by means of the same tool and the 6401 Kohler compass the width and height of the alveolar process were measured. The measurement of the width of the alveolar process was carried out in the transverse dimension using the Kohler compass at intervals of 3mm counting from the rim of the lowest alveolar lamella (assessed using the 3182 Kohler periodontal probe) to the maximum height of 12 mm (Figure 3).

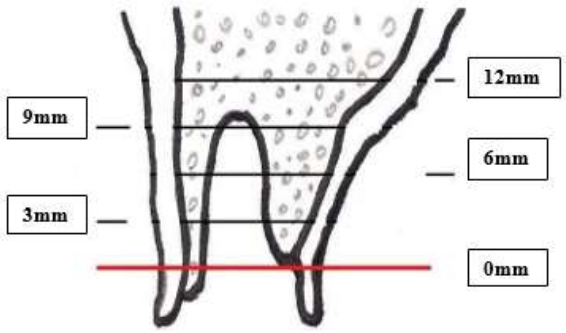

Figure 3. Alveolar transverse width measurement.

The height of the alveolar process was measured with the periodontal probe. The auxiliary reference line - the IC line drawn through the top of the buccal cusps of the teeth

adjacent to the post-extraction socket was defined for that purpose. The measurement was done in the midline of the alveolus and the distance between IC line and vestibular alveolar bone was measured. The obtained value was recorded as the HIC distance (Figure 4, Table 3).

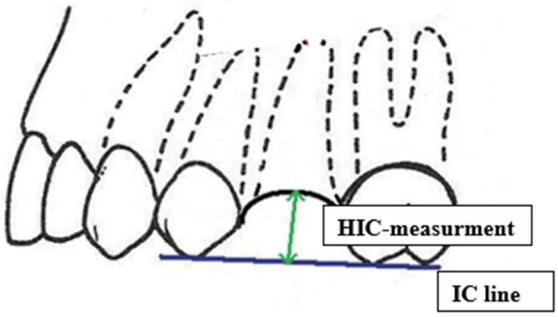

Figure 4. HIC distance measurement.

After measuring the width and height of the alveolar process of one of the post-extraction alveoli, platelet-rich fibrin was inserted so that it filled the alveolus tightly (the study group - GROUP I). Next the mucosal flap for covering the alveolus was split with the use of a scalpel with blade number 15 c.

In the case of maxillary alveoli, a rotated palatal flap was used, whereas in the case of mandibular alveoli, a mucosal flap from the oral vestibule was applied. The flaps were prepared in such a way so that it was possible to close the wound without tightening the soft tissues. Next, tight surgical wound closure was performed using 6/0 nylon stitches.

The other homonymous alveolus (the control group - Group II) was surgically managed in an analogical manner as on the other side of the dental arch with the difference that PRF was not inserted in the alveolus. After performing measurements, a rotated palatal flap was prepared in the case of maxillary teeth and a mucosal flap from the oral vestibule in the case of the mandible. Tight surgical wound closure was performed using 6/0 nylon stitches.

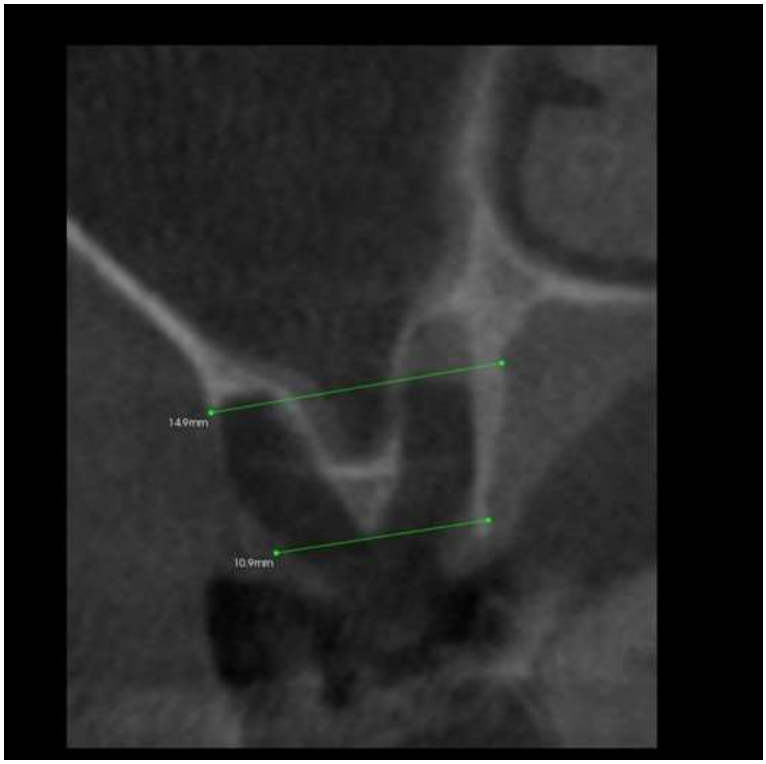

Figure 5. Transverse imaging of maxillary alveolus obtained from CBCT. The alveolus width measurement 10 days post extraction..

2.2. Postoperative Care

Patients were not prescribed any antibiotics in the postoperative period. Brushing the teeth with a soft brush at least twice a day excluding the surgical field for the period of 10 days, that is, till the day of stitches removal was recommended. On the first postoperative days, that is, up to 10 days, abstaining from food of hard consistency was recommended.

After 10 days from the surgery, the stitches were removed, and the course of the alveoli healing was clinically assessed. The notion of the Assessment Rate of Soft Tissues Healing (ARSTH) created according to authors' own ideas and for the purpose of this study. ARSTH was based on the five-grade scale including the assessment of five factors:

1. the appearance of the wound: infected – 0 points, clean – 1 point;
2. oedema: present – 0 points, not present – 1 point;
3. discharge from the wound: present – 0 points, not present – 1 point;
4. the tightness of wound closure: wound dehiscence – 0 points, tight wound closure – 1 point
5. pain reported by patient in VAS scale: 5 or more – 0 points, less than 5 – 1 point.

The patients received maximally 5 points if the wound was clean, without oedema, without discharge and tight and pain was assessed by the patient as less intense than 5 in VAS scale (Visual Analogue Scale - VAS).

Simultaneously, after 10 days from the surgery the patient was subjected to CBCT examination (cone-beam computed tomography), limited to the area of the post-extraction alveoli using the Kodak 9000 apparatus (Figure 5). And the alveolus width and height were measured.

After 6 months the measurements of the alveolar process width and height were repeated. The examination was analogical as on the day of tooth extraction.

Also 6 months after the surgery another performance of volumetric CBCT limited to the area of the post-extraction alveoli using the Kodak 9000 apparatus was recommended.

During these examinations, the alveolar process in the extraction site and Grayscale Values in the selected measurement points were measured (Figures 6-9).

After 6 months from tooth extraction Grayscale Values were assessed. To define the points of measurement the auxiliary reference lines were defined:

1. The A line drawn through the apexes of the teeth adjacent to the post-extraction socket.
2. The IC line drawn through the top of the buccal cusps of the teeth adjacent to the pos-extraction socket.
3. The Midline of the post-extraction socket (alveolus)

Then the two points of Grayscale Values were defined (Figure 8):

Point A) 1/3 of the distance between A line and IC line following the Midline

Point B) at the intersection of the Midline and A line

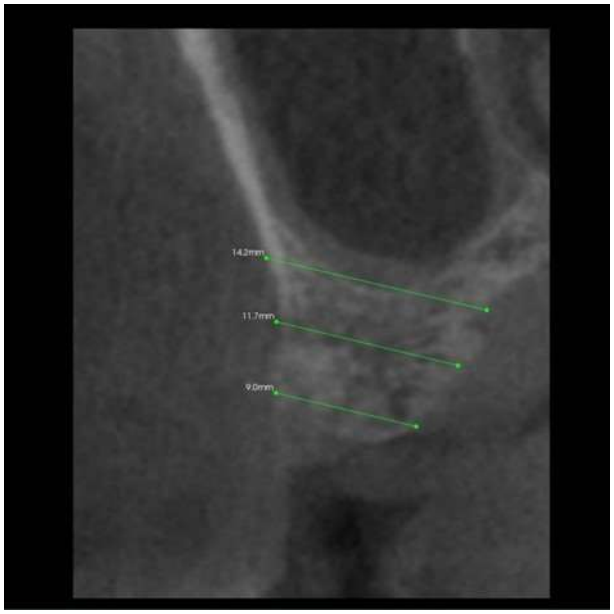

Figure 6. Transverse imaging of maxillary alveolus in CBCT. Alveolar width measurement 6 months post extraction..

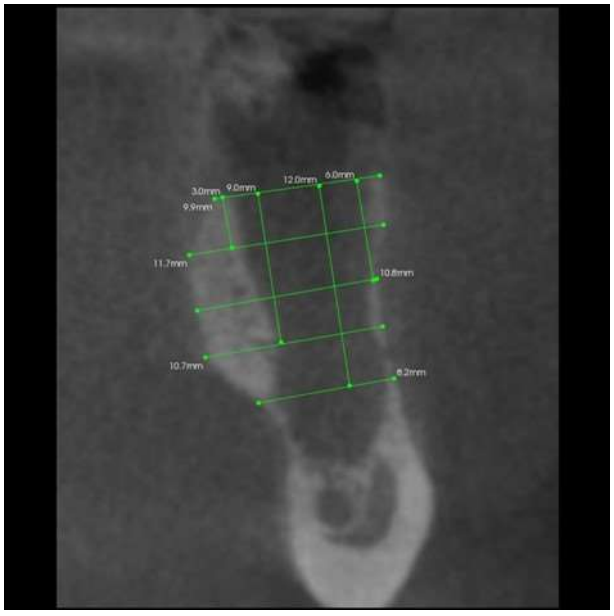

Figure 7. Transverse imaging of mandibular alveolus obtained from CBCT. The alveolus width measurement 10 days post extraction.

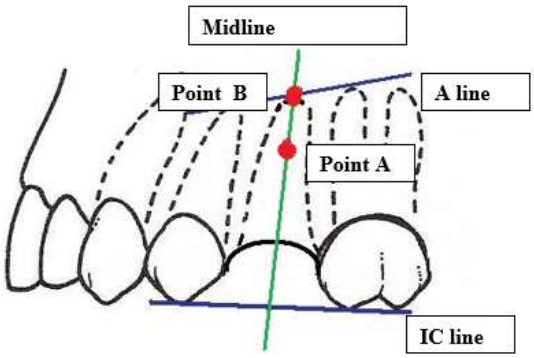

Figure 8. Grayscale Value measurement points.

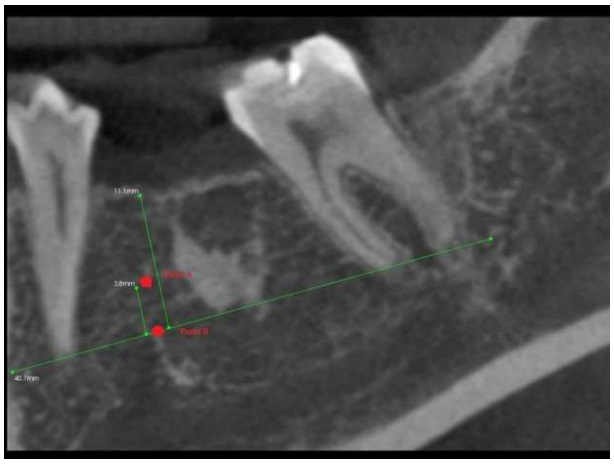

Figure 9. Longitudinal imaging of mandibular alveolus in CBCT. Grayscale Value measurement 6 months post extraction..

3. Results

An analysis of the results was carried out using the PQStat ver. 1.4.2.324. statistical package.

The study was conducted on a group of 50 patients including 22 women and 28 men aged from 18 to 59 (Figure 10). Mean age in the study group amounted to 35.68. 100 tooth extractions were performed in the patients. Molars were the most frequently extracted teeth (54%), more often upper than lower, next premolars (18%), canines (6%) and incisors (2%). Teeth with gangrenous pulp with considerable damage to the tooth crown (48 teeth) and improperly treated root canals (36) were most frequently extracted. Teeth with complications after improper treatment (16 teeth - including breaking instruments for root canal treatment, perforation of the bottom of the pulp cavity, perforation of the roots) required surgical intervention less frequently.

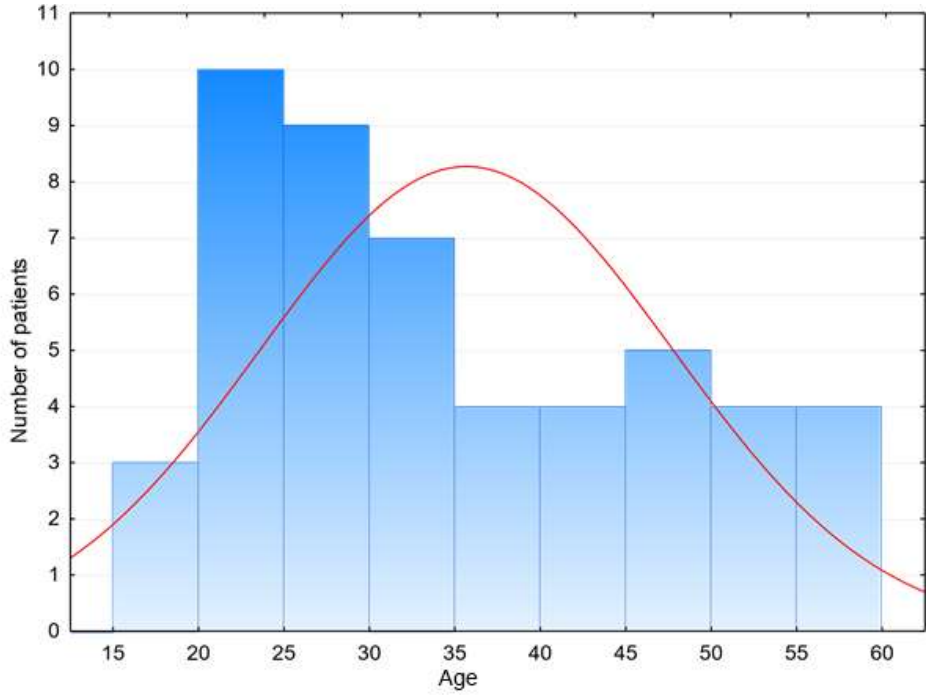

Figure 10. Age distribution in the research group.

3.1. The Assessment of Soft Tissues Healing [ARSTH] for the Alveolar Area (With and Without PRF Insertion) Assessed After 10 Days from Tooth Extraction.

After 10 days from tooth extraction more frequent wound infections were observed in the cases of extractions of teeth in which PRF was not inserted in the alveolus (p=0.0233) (Table 2). Oedema, assessed also on day 10, occurred more frequently in the alveolar area without PRF compared to the side where platelet-rich fibrin was applied but this difference is of little statistical significance. Pain occurred in Group II, the control group where platelet-rich fibrin was not used, much more frequently in comparison to the study group where PRF was used (p=0.0265) (Table 2). Wound healing complications in the form of wound dehiscence were found in isolated cases in both groups but all of them were not statistically significant (Table 2). Therefore, the positive influence of platelet-rich fibrin employment on the process of wound healing can be observed.

Table 2. Soft Tissue Healing Assessment in the group of 50 patients performer in the 10th day post extraction according to ARSTH scoring scale.

	Group I*		**Group II***		**McNemar test**
	No.	%	No.	%	
Clean wound	48	96.0	41	82.0	Chi2=5.14 **p=0.0233**
Infected wound	2	4.0	9	18.0	
No swelling	37	74.0	32	64.0	Chi2=2.29 p=0.1306
Swelling	13	26.0	18	36.0	
No discharge	48	96.0	41	82.0	Chi2=5.14 **p=0.0233**
Discharge	2	4.0	9	18.0	
VAS pain < 5	38	76.0	29	58.0	Chi2=4.92 **p=0.0265**
VAS pain > 5	12	24.0	21	42.0	
Tight wound	48	96.0	44	88.0	Chi2=1.50 p=0.2207
Wound dehiscence	2	4.0	6	12.0	

* Group I – alveoli with PRF, Group II – alveoli without PRF.

3.2. The Results of Mean Values of the Alveolar Process Width and Height Measurements Performed After Tooth Extraction Within the Space of 6 Months for Two Different Alveoli in the Same Patient.

No statistically significant differences of mean values of the alveolar process width and height (HIC distance) measurements performed directly after tooth extraction were found for the alveoli in which platelet-rich fibrin was not used in comparison to the alveoli where platelet-rich fibrin was applied (Table 3). After 6 months significant differences concerned primarily the mean values of the alveolar process width and height measurements (p=0.0085). Larger values were observed in Group I where PRF was used. In the PRF group mean width measurement amounted to 9.43mm ± 1.74mm, whereas in the group without PRF it amounted to 9.15mm ± 1.51mm (Table 3). Within the space of 6 months changes in the mean values of the measurements of the alveoli width were significant (p=0.0016) (Table 3). In the platelet-rich fibrin group the average loss of the alveolar process amounted to 1.49mm ± 0.84mm, whereas in the non-PRF group it amounted to 1.85mm ± 0.86mm (Table 3).

Table 3. The mean values of alveolar width and height in Group I (PRF) and Group II (no PRF) measured 10 days and 6 months post extraction and the change of values in time.

			Descriptive statistics							
Variable	Time post extraction	Group	Mean	Standard deviation	Minimum	Lower quartile	Median	Upper quartile	Maximum	Wilcoxon signed-rank test
Alveolar width	0 days	I	10.92	2.15	7.0	9.0	11.3	13.0	14.5	Z=0.83
		II	11.01	1.95	7.0	10.0	11.0	12.0	14.0	p=0.4043
	6 months	I	9.43	1.74	5.5	8.0	9.8	11.0	12.5	Z=2.63
		II	9.16	1.51	6.0	8.0	9.5	10.0	12.0	**p=0.0085**
HIC	0 days	I	9.05	1.27	7.0	8.5	9.0	10.0	12.0	Z=0.47
		II	9.01	1.21	7.0	8.0	9.0	10.0	12.0	p=0.6402
	6 months	I	10.84	1.19	9.0	10.0	11.0	11.5	13.0	Z=1.17
		II	11.01	1.26	8.5	10.0	11.0	12.0	14.5	p=0.2418
Width change (bone loss)		I	1.49	0.84	0.5	1.0	1.5	2.0	4.5	Z=3.16
		II	1.85	0.86	0.0	1.5	2.0	2.5	4.5	**p=0.0016**
Height change (bone loss)		I	1.79	0.61	0.5	1.5	1.5	2.0	3.0	Z=2.03
		II	1.98	0.76	0.5	1.5	2.0	2.5	4.5	**p=0.0426**

* Group I – alveoli with PRF, Group II – alveoli without PRF.

3.3. The Results of Mean Values of Grayscale Value Measurements for Two Alveoli (With/Without PRF Insertion) after 6 Months.

The highly significant differences of the distribution of Grayscale values were found in volumetric tomography in point A (in 1/3 of the section from the side of the alveolar apex) between Group I, that is the alveoli in which platelet-rich fibrin was used and Group II, that is the control group in which platelet-rich fibrin was not inserted in the alveolus (p=0.0097). The higher results of this measurement concern Group I and amount to 308.16 ± 128.51, whereas in the non- PRF group they amounted to 279.4 ± 136.23 (Table 4).

The highly significant differences of the distribution of Grayscale values were also found in volumetric tomography in point B (at the intersection of the midline of the alveolus and the line drawn through the adjacent teeth apexes) and again the higher results of this measurement concern Group I, that is the alveoli where platelet-rich fibrin was used, and amounted to 333.1 ± 131.22, whereas in the non-PRF group 305.54 ± 139.12 (Table 4).

Table 4. Mean values of GVs in CBCT.

Variable	Group	Descriptive statistics							
		Mean	**Standard deviation**	**Minimum**	**Lower quartile**	**Median**	**Upper quartile**	**Maximum**	**Wilcoxon signed-rank test**
GV (point A)	I	308.16	128.15	55.0	226.0	282.5	441.0	557.0	Z=2.59
	II	279.40	136.23	75.0	162.0	256.0	390.0	576.0	**p=0.0097**
GV (point B)	I	331.10	131.22	98.0	250.0	301.5	473.0	636.0	Z=2.59
	II	305.54	139.12	87.0	187.0	289.0	428.0	623.0	**p=0.0097**

* Group I – alveoli with PRF, Group II – alveoli without PRF.

3.4. The Results of Mean Measurements of Height and Width of the Alveolar Processes of Two Extraction Sites (With and Without PRF) in the Same Patient After 6 Months from Tooth Extraction on the Basis of the Analysis of Volumetric Tomography.

A statistically significant (p=0.0148) change in the six-month period of observation was found with reference to the mean values of measurements of the height of the alveolar process with larger bone atrophy for the alveoli in which PRF was not inserted. The atrophy in Group I with PRF amounted to 1.59mm ± 0.49mm, whereas in Group II without PRF amounted to 1.85mm ± 0.75mm (Table 5). Also, a statistically significant (p=0.0479) change of the values of measurements of the width of the alveolar process performed using CBCT was observed. In Group I with PRF this change amounted to 0.87mm ±0.4mm and in the non-PRF group 1.18mm ± 1.1mm (Table 5).

Table 5. Mean alveolar width and height 10 days and 6 months pod extraction (with and without PRF) and changes observed in CBCT examination.

Variable	Time post extraction	Group	Descriptive statistics							
			Mean	Standard deviation	Minimum	Lower quartile	Median	Upper quartile	Maximum	Wilcoxon signed-rank test
Alveolar width	0 days	I	12.53	2.51	8.0	10.5	12.0	14.5	17.5	Z=1.49
		II	12.70	2.32	8.5	11.0	12.0	15.0	18.0	p=0.1357
	6 months	I	11.66	2.34	7.0	10.0	11.5	13.0	16.0	Z=0.51
		II	11.52	1.96	8.0	10.0	11.0	13.0	16.0	p=0.6105
Alveolar height	0 days	I	9.70	1.95	6.0	8.0	9.5	11.0	14.0	Z=0.72
		II	9.71	1.87	6.0	8.0	9.5	11.0	14.0	p=0.4692
	6 months	I	8.09	1.91	4.5	7.0	8.0	9.5	12.5	Z=1.07
		II	7.96	2.00	4.0	6.5	7.8	10.0	12.0	p=0.2854
Width change (bone loss)		I	0.87	0.60	0.0	0.5	1.0	1.0	3.0	Z=1.78
		II	1.18	1.10	0.0	0.5	1.0	2.0	4.0	p=0.0749
Height change (bone loss)		I	1.59	0.49	0.5	1.0	1.5	2.0	2.5	Z=2.44
		II	1.85	0.75	0.0	1.5	2.0	2.0	4.0	**p=0.0148**

* Group I – alveoli with PRF, Group II – alveoli without PRF.

4. Discussion

Many authors have been looking for an ideal way of preventing the bone atrophy of the alveolar process after tooth extraction for a long time. Hope is pinned on both ideal bone graft substitutes and various surgical techniques, all the more so as, in the light of contemporary literature, this atrophy reaches the values of 40-60 % of the volume of the

process from before tooth extraction [29,30]. The preservation of the alveolar process of the initial width and height provides the foundation for later implantation or aesthetic prosthetic works [31,32].

The preservation of the periosteum without damaging it while preparing the flap minimizes, according to Sclar et al., the loss of the buccal bone lamella [33]. Split flap preparation aimed at covering the alveoli may have a significant influence on alveolar vascularization and thus, on the preservation of living osteoblasts and their stimulation for bone regeneration. In this study, only platelet-rich fibrin was used for filling the alveolus. PRF was covered with a flap from the side of the oral cavity proper to avoid incisions from the side of the oral vestibule involving damage to the periosteum and the disturbance of the bone healing process through accelerating bone resorption. Covering platelet-rich fibrin (PRF) was aimed at its protection against falling out from the post-extraction alveolus or dissolving. PRF is an autologous and biocompatible material which does not contain any additives. It is cheap and easy to prepare. While performing everyday surgical procedures, it does not take longer that a few additional minutes to collect and centrifuge full venous blood.

The purpose of this study was to compare the behavior of the alveolar bone after tooth extraction and platelet-rich fibrin application and the healing of the alveolus without applying any material. The alveoli of two homonymous teeth in the same patient in the presence of the teeth adjacent to the post-extraction alveolus were compared. Many authors who concentrate their research on the prevention of the alveolar process atrophy compare in their studies random alveoli included either in the control group or the study group [1,4,29,30,34,35]. Using the predilection of the patients who had two homonymous mandibular or maxillary teeth, groups of patients were selected in the most comparable manner. Also, patients burdened with systemic diseases as well as patients with addictions were excluded from the study to prevent the disturbance of the bone healing process.

In the study, the alveoli healing was observed on day 10 after surgery. The authors of numerous studies assess the healing process on day 14 after surgery [4,29,31,34]. However, if the assessment of soft tissues healing is too late, it may have a significant influence on study results since with time the total healing of tissues in both groups occurs, which was mentioned by Lauren et al. in their publication [35].

The last follow-up examination was performed after 6 months. The majority of authors assess the width and height of the bone in their reports after 6 months when it is thought that the initial period of bone healing and mineralization came to an end [1,35]. However, the assessment of the bone should be performed after its good mineralization because in the case of poor mineralization it will not be visible in radiological examinations, thus the assessment of the density and structure of the newly formed bone will be distorted [36,37]. For the assessment of the width and height of the alveolar process cone beam computed tomography CBCT was used. In the assessment of newly formed bone the Grayscale Values (GVs).

The study was conducted at the end of 2011 and at the beginning of 2012 on a group of 50 patients aged from 18 to 59. In the assessment of soft tissues healing, authors' own assessment rate of soft tissues healing [ARSTH] created for the purposes of this study was employed. The rate was based on the five-grade scale of the assessment of post-extraction wound healing. The statistical analysis of ARSTH on day 10 after surgery revealed a highly statistically significant difference of results in the study group and the control group. It was demonstrated that healing in the group of alveoli with PRF insertion proceeds faster and with a smaller number of reported complications. The results obtained show that the employment of platelet-rich fibrin prevents infections. In the study group, in which PRF was used, wound infections occurred less frequently, 4% of the cases in Group I (where PRF was used) and as many as 18% of the cases in Group II. Also wound discharge occurred less frequently, namely in 4% of the cases in Group I and as many as 18% of the cases in Group II. However, a statistically significant difference in the assessment of pain on day 10 after tooth extraction was demonstrated. Pain occurred in 24% of

the cases in Group I with PRF, whereas in Group II pain occurred in 42% of the cases. These results confirm that PRF may have an anti-inflammatory effect and prevent infections. It coincides with expectations of this material. Dohan Ehrenfest, who is the author of numerous publications on PRF, proved the high concentration of not only platelets, but also leucocytes in a PRF clot obtained according to Choukroun's protocol [38,39]. Anti-inflammatory properties and a regulating effect on the immune response were revealed [13,40]. Leukocytes are responsible also for the production of large amounts of VEGF [41]. The additional advantage of using this biomaterial as a separate means of preventing the atrophy of the alveolar process is a faster and less complicated surgery not exposing the patient to the risk of complications such as infection and in the case of using collagen membranes also the increased risk of wound dehiscence [42].

In the conducted study, the measurements of width and height of the alveolar process were performed directly after tooth extraction and follow-up examinations were carried out after 6 months, that is after the time of the alveolar bone healing and remodeling. It was found in the study that statistically significant differences concerned Group I where PRF was applied, thereby preventing the atrophy of the alveolar process in the horizontal dimension. In the PRF group the average loss of the alveolar process amounted to 1.49mm ± 0.84mm and in the non-PRF group 1.85mm ± 0.86mm (Table 3). The employment of platelet-rich fibrin causes the growth factors contained in it to stimulate cells to differentiate faster and to produce new bone, thanks to which the decreased atrophy of the alveolar bone in the transverse dimension occurred. In in vitro studies from 2010, Dohan Ehrenfest et al. [43] proved that the release of growth factors from platelet-rich fibrin is a long-lasting process. It lasts even up to 14 days and has a stimulating effect on all cell types. They proved the release of five most important growth factors. The concentration of these factors remained at the same level for the first few days and only then is started to decrease. Leitner et al. publish similar results [44]. O'Connell and Carrol's research proved that the use of bovine thrombin in the course of obtaining PRF may lead to the immediate the degranulation of alpha granules and cause the release of all these growth factors [45]. Therefore, it will lead to the very high concentration of growth factors at the beginning of the healing phase but after a few hours this concentration will decrease, and the stimulating effect of growth factors will cease.

A large amount of full value, high-density bone is one of the conditions of aesthetic implantoprosthetic reconstruction. Properly structured bone of a higher degree of mineralization is less susceptible to the resorption process, thus it ensures a higher percentage of successes in implantological treatment as well as it contributes to better long-term effects in the case prosthetic treatment [46]. However, the bone will not be of good quality after the healing of the alveolus in each patient. Therefore, the physician's and patient's appropriate conduct before deciding on tooth extraction is important. It was proved as well that the mineral density of the osseous tissue reflects the biological activity of the bone, thus attempts are being made to assess bone density using such a simple examination as CBCT and in that way determine its activity [47]. Nevertheless, it is proven that CBCT equipment calibration and further conversion steps are needed in order to reliably asses the bone density in CBCT imaging [48]. Due to imaging being performed at remote facility this was impossible, which constitutes the limitation of this study. Therefore the result of the measurements need to be referenced as Grayscale Values rather than Hounsfield Units.

On the other hand there are reports on correlation between CBCT derived bone GVs and the subjective tactile sensation of the perceived bone quality during implant placement. Abdulkarim et al. reported on correlation between CBCT bone GVs and clinical bone quality, which was stronger in absence of bone grafting material and weaker with graft, especially xenograft [49]. In our research the grafting material was completely absorbable so it was not affecting the measurements [50]. Moreover numerous papers backing a correlation between CBCT derived bone GVs and primary and secondary implant stability, which is clinically significant parameter, were published [51–55]. Nevertheless

the literature data on those correlations is ambiguous, which has to be taken into consideration when drawing conclusions [50].

In the study, an attempt to assess the influence of platelet-rich fibrin on the newly formed bone was made. The authors' own research demonstrated significant differences in the Grayscale Values of the newly formed bone after 6 months. Differences between the groups in favor of Group I i.e., the group with PRF in the alveolus were revealed. This might mean that the use of PRF might improve primary and secondary implant stability at extraction site. The reason for this may be growth factors being active in the initial phase of healing which leads to the process of osseous bridges formation as well as faster callus formation and its mineralization. It is important for the acceleration of tissues healing that growth factors are present in the wound for a longer period. Thanks to the longer presence, their positive impact first on soft tissues healing and then bone healing is possible because the short-term influence of growth factors in the wound could make no contribution to the acceleration and improvement of healing [43].

The accuracy of CBCT examination is good enough to use this method for the thorough analysis of the alveolar bone and today's apparatuses make this examination involve very small doses of radiation. In the study, the width and height of the alveolar process were measured after tooth extraction and after 6 months, thereby making it possible to precisely examine the amount of bone. A statistically significant change in the width of the alveolar process was observed. It amounted on average to 0.87mm ± 0.4mm in Group I with the use of PRF, that is the average loss amounted to 6.9% to the width of the bone, whereas in Group II without PRF, the average loss amounted to 1.18mm ± 1.1mm, i.e., 9.4%. On the other hand, a statistically significant ($p=0.0148$) change in the height of the alveolar process was also revealed within the space of 6 months of observation. In Group I with PRF the change/loss amounted on average to 1.59mm ± 0.49mm, i.e., the loss of 14.1% of the height, while in Group II without PRF, it amounted to 1.85mm ± 0.75mm, i.e. 21.5%. It can be concluded that these results correlate with various previous scientific reports and bone atrophy in the horizontal and transverse dimension should be expected [1–5]. In the light of available literature, bone atrophy amounts on average to 25-30% after the period of 6 months [1,2]. In this study bone atrophy amounted to definitely less than in the above-mentioned scientific reports both in the study group and the control group. However, it is believed that this result is related to the atraumatic technique of tooth extraction together with covering the open alveolus with a flap, which has a significant influence on thrombus formation and its remodeling.

The research conducted revealed the possibility of preventing the atrophy of the alveolar process in the site of the extracted tooth through guided bone regeneration using entirely autologous material such as platelet-rich fibrin. The technique of securing platelet-rich fibrin in the alveolus so that it was as atraumatic as possible for the patient requires further observation and elaboration.

5. Conclusions

Platelet-rich fibrin influences the reduction of the bone resorption process in the healing of the alveolus after tooth extraction. The use of platelet-rich fibrin improves also soft tissues healing and the healing of the post-extraction alveolus.

Author Contributions: Conceptualization, Iwona Niedzielska and Daniel Ciapiński; Data curation, Daniel Ciapiński; Investigation, Daniel Ciapiński and Damian Niedzielski; Methodology, Iwona Niedzielska, Daniel Ciapiński, Michał Bąk and Damian Niedzielski; Validation, Iwona Niedzielska; Visualization, Michał Bąk; Writing – original draft, Iwona Niedzielska, Daniel Ciapiński, Michał Bąk and Damian Niedzielski; Writing – review & editing, Iwona Niedzielska and Michał Bąk.

Funding: This research received no external funding.

Institutional Review Board Statement: The study was conducted in accordance with the Declaration of Helsinki and approved by the bioethics committee of Medical University of Silesia (protocol KNW/0022/KB1/97/II/10/11).

Informed Consent Statement: Informed consent was obtained from all subjects involved in the study.

Conflicts of Interest: The authors declare no conflict of interest.

References

1. Araújo, M.G.; Lindhe, J. Dimensional Ridge Alterations Following Tooth Extraction. An Experimental Study in the Dog. *J Clin Periodontol* **2005**, *32*, 212–218, doi:10.1111/j.1600-051X.2005.00642.x.
2. Nevinis, M.; Mellonig, J. In *Implant Therapy. Clinical Approaches and Evidence of Success.*; pp. 23–28.
3. Dominiak, M.; Łysiak, K. Odbudowa struktury kostnej w ubytkach poekstrakcyjnych - aspekty procesów fizjologicznych i regeneracyjnych po zastosowaniu biomateriałów - przegląd piśmiennictwa. *Poradnik Stomatologiczny* **2004**, *4*.
4. Ashman, A. Ridge Preservation: Important Buzzwords in Dentistry. *Gen Dent* **2000**, *48*, 304–312.
5. Lekovic, V.; Camargo, P.M.; Klokkevold, P.R.; Weinlaender, M.; Kenney, E.B.; Dimitrijevic, B.; Nedic, M. Preservation of Alveolar Bone in Extraction Sockets Using Bioabsorbable Membranes. *J Periodontol* **1998**, *69*, 1044–1049, doi:10.1902/jop.1998.69.9.1044.
6. Darby, I.; Chen, S.T.; Buser, D. Ridge Preservation Techniques for Implant Therapy. *Int J Oral Maxillofac Implants* **2009**, *24 Suppl*, 260–271.
7. Araújo, M.G.; Lindhe, J. Ridge Alterations Following Tooth Extraction with and without Flap Elevation: An Experimental Study in the Dog. *Clin Oral Implants Res* **2009**, *20*, 545–549, doi:10.1111/j.1600-0501.2008.01703.x.
8. Simon, B.I.; Von Hagen, S.; Deasy, M.J.; Faldu, M.; Resnansky, D. Changes in Alveolar Bone Height and Width Following Ridge Augmentation Using Bone Graft and Membranes. *J Periodontol* **2000**, *71*, 1774–1791, doi:10.1902/jop.2000.71.11.1774.
9. Zubillaga, G.; Von Hagen, S.; Simon, B.I.; Deasy, M.J. Changes in Alveolar Bone Height and Width Following Post-Extraction Ridge Augmentation Using a Fixed Bioabsorbable Membrane and Demineralized Freeze-Dried Bone Osteoinductive Graft. *J Periodontol* **2003**, *74*, 965–975, doi:10.1902/jop.2003.74.7.965.
10. Marciniak, J. *Biomateriały*; Wydawnictwo Politechniki Śląskiej: Gliwice, 2002;
11. Choukroun, J.; Adda, F.; Schoeffler, C.; Vervelle, A. Une Opportunite´ En Paro-Implantologie: Le PRF. *Implantodontie* **2001**.
12. Diss, A.; Dohan, D.M.; Mouhyi, J.; Mahler, P. Osteotome Sinus Floor Elevation Using Choukroun's Platelet-Rich Fibrin as Grafting Material: A 1-Year Prospective Pilot Study with Microthreaded Implants. *Oral Surg Oral Med Oral Pathol Oral Radiol Endod* **2008**, *105*, 572–579, doi:10.1016/j.tripleo.2007.08.021.
13. Dohan, D.M.; Choukroun, J.; Diss, A.; Dohan, S.L.; Dohan, A.J.J.; Mouhyi, J.; Gogly, B. Platelet-Rich Fibrin (PRF): A Second-Generation Platelet Concentrate. Part II: Platelet-Related Biologic Features. *Oral Surg Oral Med Oral Pathol Oral Radiol Endod* **2006**, *101*, e45-50, doi:10.1016/j.tripleo.2005.07.009.
14. Dohan, D.M.; Choukroun, J.; Diss, A.; Dohan, S.L.; Dohan, A.J.J.; Mouhyi, J.; Gogly, B. Platelet-Rich Fibrin (PRF): A Second-Generation Platelet Concentrate. Part III: Leucocyte Activation: A New Feature for Platelet Concentrates? *Oral Surg Oral Med Oral Pathol Oral Radiol Endod* **2006**, *101*, e51-55, doi:10.1016/j.tripleo.2005.07.010.
15. Choukroun, J.; Diss, A.; Simonpieri, A.; Girard, M.-O.; Schoeffler, C.; Dohan, S.L.; Dohan, A.J.J.; Mouhyi, J.; Dohan, D.M. Platelet-Rich Fibrin (PRF): A Second-Generation Platelet Concentrate. Part IV: Clinical Effects on Tissue Healing. *Oral Surg Oral Med Oral Pathol Oral Radiol Endod* **2006**, *101*, e56-60, doi:10.1016/j.tripleo.2005.07.011.
16. Choukroun, J.; Diss, A.; Simonpieri, A.; Girard, M.-O.; Schoeffler, C.; Dohan, S.L.; Dohan, A.J.J.; Mouhyi, J.; Dohan, D.M. Platelet-Rich Fibrin (PRF): A Second-Generation Platelet Concentrate. Part V: Histologic Evaluations of PRF

Effects on Bone Allograft Maturation in Sinus Lift. *Oral Surg Oral Med Oral Pathol Oral Radiol Endod* **2006**, *101*, 299–303, doi:10.1016/j.tripleo.2005.07.012.

17. Carroll, R.; Amoczky, S.; Graham, S.; O'Connell, S. Characterization of Autologous Growth Factors in Cascade Platelet Rich Fibrin Matrix (PRFM). *Musculoskeletal Transplant Foundation. Edison, NJ* **2005**.
18. Dohan Ehrenfest, D.M.; Bielecki, T.; Jimbo, R.; Barbé, G.; Del Corso, M.; Inchingolo, F.; Sammartino, G. Do the Fibrin Architecture and Leukocyte Content Influence the Growth Factor Release of Platelet Concentrates? An Evidence-Based Answer Comparing a Pure Platelet-Rich Plasma (P-PRP) Gel and a Leukocyte- and Platelet-Rich Fibrin (L-PRF). *Curr Pharm Biotechnol* **2012**, *13*, 1145–1152, doi:10.2174/138920112800624382.
19. Dohan, D.M.; Del Corso, M.; Charrier, J.-B. Cytotoxicity Analyses of Choukroun's Platelet-Rich Fibrin (PRF) on a Wide Range of Human Cells: The Answer to a Commercial Controversy. *Oral Surgery, Oral Medicine, Oral Pathology, Oral Radiology and Endodontics* **2007**, *103*, 587–593, doi:10.1016/j.tripleo.2007.03.016.
20. Dohan, D.M.; Choukroun, J.; Diss, A.; Dohan, S.L.; Dohan, A.J.J.; Mouhyi, J.; Gogly, B. Platelet-Rich Fibrin (PRF): A Second-Generation Platelet Concentrate. Part I: Technological Concepts and Evolution. *Oral Surg Oral Med Oral Pathol Oral Radiol Endod* **2006**, *101*, e37-44, doi:10.1016/j.tripleo.2005.07.008.
21. Bilgen, F.; Ural, A.; Bekerecioglu, M. Platelet-Rich Fibrin: An Effective Chronic Wound Healing Accelerator. *J Tissue Viability* **2021**, *30*, 616–620, doi:10.1016/j.jtv.2021.04.009.
22. Thorat, M.; Pradeep, A.R.; Pallavi, B. Clinical Effect of Autologous Platelet-Rich Fibrin in the Treatment of Intra-Bony Defects: A Controlled Clinical Trial. *J Clin Periodontol* **2011**, *38*, 925–932, doi:10.1111/j.1600-051X.2011.01760.x.
23. Sharma, A.; Pradeep, A.R. Treatment of 3-Wall Intrabony Defects in Patients with Chronic Periodontitis with Autologous Platelet-Rich Fibrin: A Randomized Controlled Clinical Trial. *J Periodontol* **2011**, *82*, 1705–1712, doi:10.1902/jop.2011.110075.
24. Heggendorn, F.L.; Heggendorn, C.; Vidal, F.; Silva, G.C. de C.; Gonçalves, L.S.; Lione, V. de O.F. Leukocyte-Platelet Rich Fibrin on the Treatment of a Large Paradental Cyst: A Novel Regenerative Approach. *Blood Coagul Fibrinolysis* **2021**, *32*, 411–417, doi:10.1097/MBC.0000000000001029.
25. Nagaraja, S.; Mathew, S.; Jain, N.; Jethani, B.; Nambiar, S.; Kumari, M.; Nair, S. Study of Antibacterial and Antifungal Efficacy of Platelet-Rich Fibrin and Platelet-Rich Fibrin Matrix. *J Conserv Dent* **2019**, *22*, 415–419, doi:10.4103/JCD.JCD_100_19.
26. Petrescu, B.N.; Mirica, I.C.; Miron, R.; Campian, R.S.; Lucaciu, O. Platelet Rich Fibrin as a Gingival Tissue Regeneration Enhancer. *J Dent Sci* **2021**, *16*, 536–539, doi:10.1016/j.jds.2020.08.014.
27. Kempraj, J.; Sundaram, S.S.; Doss, G.P.T.; Nakeeran, K.P.; Raja, V.B.K.K. Maxillary Sinus Augmentation Using Xenograft and Choukroun's Platelet-Rich Fibrin as Grafting Material: A Radiological Study. *J Maxillofac Oral Surg* **2020**, *19*, 263–268, doi:10.1007/s12663-019-01197-x.
28. Sunitha Raja, V.; Munirathnam Naidu, E. Platelet-Rich Fibrin: Evolution of a Second-Generation Platelet Concentrate. *Indian J Dent Res* **2008**, *19*, 42–46, doi:10.4103/0970-9290.38931.
29. Barone, A.; Aldini, N.N.; Fini, M.; Giardino, R.; Calvo Guirado, J.L.; Covani, U. Xenograft versus Extraction Alone for Ridge Preservation after Tooth Removal: A Clinical and Histomorphometric Study. *J Periodontol* **2008**, *79*, 1370–1377, doi:10.1902/jop.2008.070628.
30. Iasella, J.M.; Greenwell, H.; Miller, R.L.; Hill, M.; Drisko, C.; Bohra, A.A.; Scheetz, J.P. Ridge Preservation with Freeze-Dried Bone Allograft and a Collagen Membrane Compared to Extraction Alone for Implant Site Development: A Clinical and Histologic Study in Humans. *J Periodontol* **2003**, *74*, 990–999, doi:10.1902/jop.2003.74.7.990.

31. Crespi, R.; Capparè, P.; Gherlone, E. Dental Implants Placed in Extraction Sites Grafted with Different Bone Substitutes: Radiographic Evaluation at 24 Months. *J Periodontol* **2009**, *80*, 1616–1621, doi:10.1902/jop.2009.090156.
32. Nevins, M.; Mellonig, J.T.; Clem, D.S.; Reiser, G.M.; Buser, D.A. Implants in Regenerated Bone: Long-Term Survival. *Int J Periodontics Restorative Dent* **1998**, *18*, 34–45.
33. Sclar, A.G. The Bio-Col Technique. In *Soft Tissue and Esthetic Considerations in Implant Therapy*; Quintessence, 2003; pp. 75–112.
34. Lekovic, V.; Kenney, E.B.; Weinlaender, M.; Han, T.; Klokkevold, P.; Nedic, M.; Orsini, M. A Bone Regenerative Approach to Alveolar Ridge Maintenance Following Tooth Extraction. Report of 10 Cases. *J Periodontol* **1997**, *68*, 563–570, doi:10.1902/jop.1997.68.6.563.
35. Brownfield, L.A.; Weltman, R.L. Ridge Preservation with or without an Osteoinductive Allograft: A Clinical, Radiographic, Micro-Computed Tomography, and Histologic Study Evaluating Dimensional Changes and New Bone Formation of the Alveolar Ridge. *J Periodontol* **2012**, *83*, 581–589, doi:10.1902/jop.2011.110365.
36. Trisi, P.; Rebaudi, A.; Calvari, F.; Lazzara, R.J. Sinus Graft with Biogran, Autogenous Bone, and PRP: A Report of Three Cases with Histology and Micro-CT. *Int J Periodontics Restorative Dent* **2006**, *26*, 113–125.
37. Marsell, R.; Einhorn, T.A. THE BIOLOGY OF FRACTURE HEALING. *Injury* **2011**, *42*, 551–555, doi:10.1016/j.injury.2011.03.031.
38. Dohan Ehrenfest, D.M.; Rasmusson, L.; Albrektsson, T. Classification of Platelet Concentrates: From Pure Platelet-Rich Plasma (P-PRP) to Leucocyte- and Platelet-Rich Fibrin (L-PRF). *Trends Biotechnol* **2009**, *27*, 158–167, doi:10.1016/j.tibtech.2008.11.009.
39. Dohan Ehrenfest, D.M.; Del Corso, M.; Diss, A.; Mouhyi, J.; Charrier, J.-B. Three-Dimensional Architecture and Cell Composition of a Choukroun's Platelet-Rich Fibrin Clot and Membrane. *J Periodontol* **2010**, *81*, 546–555, doi:10.1902/jop.2009.090531.
40. El-Sharkawy, H.; Kantarci, A.; Deady, J.; Hasturk, H.; Liu, H.; Alshahat, M.; Van Dyke, T.E. Platelet-Rich Plasma: Growth Factors and pro- and Anti-Inflammatory Properties. *J Periodontol* **2007**, *78*, 661–669, doi:10.1902/jop.2007.060302.
41. Werther, K.; Christensen, I.J.; Nielsen, H.J. Determination of Vascular Endothelial Growth Factor (VEGF) in Circulating Blood: Significance of VEGF in Various Leucocytes and Platelets. *Scand J Clin Lab Invest* **2002**, *62*, 343–350, doi:10.1080/00365510260296492.
42. Becker, W.; Dahlin, C.; Becker, B.E.; Lekholm, U.; van Steenberghe, D.; Higuchi, K.; Kultje, C. The Use of E-PTFE Barrier Membranes for Bone Promotion around Titanium Implants Placed into Extraction Sockets: A Prospective Multicenter Study. *Int J Oral Maxillofac Implants* **1994**, *9*, 31–40.
43. Dohan Ehrenfest, D.M.; Doglioli, P.; de Peppo, G.M.; Del Corso, M.; Charrier, J.-B. Choukroun's Platelet-Rich Fibrin (PRF) Stimulates in Vitro Proliferation and Differentiation of Human Oral Bone Mesenchymal Stem Cell in a Dose-Dependent Way. *Arch Oral Biol* **2010**, *55*, 185–194, doi:10.1016/j.archoralbio.2010.01.004.
44. Leitner, G.C.; Gruber, R.; Neumüller, J.; Wagner, A.; Kloimstein, P.; Höcker, P.; Körmöczi, G.F.; Buchta, C. Platelet Content and Growth Factor Release in Platelet-Rich Plasma: A Comparison of Four Different Systems. *Vox Sang* **2006**, *91*, 135–139, doi:10.1111/j.1423-0410.2006.00815.x.
45. O'Connell, S.; Carroll, R.; Beavis, A.; Arnoczky, S.P. Flow Cytometric Characterization of Cascade Platelet-Rich Fibrin Matrix (PRFM); The Impact of Exogenous Thrombin on Platelet Concentrates (PC). *Musculoskeletal Transplant Foundation. Edison, NJ* **2006**, *4*, 66.

46. Taylor, T.; Gans, S.; Jones, E.; Firestone, A.; Johnston, W.; Kim, D.-G. Comparison of Micro-CT and Cone Beam CT-Based Assessments for Relative Difference of Grey Level Distribution in a Human Mandible. *Dentomaxillofac Radiol* **2013**, *42*, 25117764, doi:10.1259/dmfr/25117764.
47. Kim, D.-G. Can Dental Cone Beam Computed Tomography Assess Bone Mineral Density? *J Bone Metab* **2014**, *21*, 117–126, doi:10.11005/jbm.2014.21.2.117.
48. Eguren, M.; Holguin, A.; Diaz, K.; Vidalon, J.; Linan, C.; Pacheco-Pereira, C.; Lagravere Vich, M.O. Can Gray Values Be Converted to Hounsfield Units? A Systematic Review. *Dentomaxillofac Radiol* **2022**, *51*, 20210140, doi:10.1259/dmfr.20210140.
49. Abdulkarim, H.H.; Zeng, R.; Pazdernik, V.K.; Davis, J.M. Effect of Bone Graft on the Correlation between Clinical Bone Quality and CBCT-Determined Bone Density: A Pilot Study. *J Contemp Dent Pract* **2021**, *22*, 756–762.
50. Schnutenhaus, S.; Götz, W.; Dreyhaupt, J.; Rudolph, H.; Luthardt, R.G.; Edelmann, C. Associations among Primary Stability, Histomorphometric Findings, and Bone Density: A Prospective Randomized Study after Alveolar Ridge Preservation with a Collagen Cone. *Dent J (Basel)* **2020**, *8*, 112, doi:10.3390/dj8040112.
51. Ivanova, V.; Chenchev, I.; Zlatev, S.; Mijiritsky, E. Correlation between Primary, Secondary Stability, Bone Density, Percentage of Vital Bone Formation and Implant Size. *Int J Environ Res Public Health* **2021**, *18*, 6994, doi:10.3390/ijerph18136994.
52. Al-Jamal, M.F.J.; Al-Jumaily, H.A. Can the Bone Density Estimated by CBCT Predict the Primary Stability of Dental Implants? A New Measurement Protocol. *J Craniofac Surg* **2021**, *32*, e171–e174, doi:10.1097/SCS.0000000000006991.
53. Isoda, K.; Ayukawa, Y.; Tsukiyama, Y.; Sogo, M.; Matsushita, Y.; Koyano, K. Relationship between the Bone Density Estimated by Cone-Beam Computed Tomography and the Primary Stability of Dental Implants. *Clinical Oral Implants Research* **2012**, *23*, 832–836, doi:10.1111/j.1600-0501.2011.02203.x.
54. Salimov, F.; Tatli, U.; Kürkçü, M.; Akoğlan, M.; Oztunç, H.; Kurtoğlu, C. Evaluation of Relationship between Preoperative Bone Density Values Derived from Cone Beam Computed Tomography and Implant Stability Parameters: A Clinical Study. *Clin Oral Implants Res* **2014**, *25*, 1016–1021, doi:10.1111/clr.12219.
55. Wada, M.; Suganami, T.; Sogo, M.; Maeda, Y. Can We Predict the Insertion Torque Using the Bone Density around the Implant? *Int J Oral Maxillofac Surg* **2016**, *45*, 221–225, doi:10.1016/j.ijom.2015.09.013.