applied sciences

MDPI

Article

Antlerogenic stem cells from Cervus elaphus accelerate corneal burn reepithelization in rabbits

Wojciech Dziewiszek[1], Marek Bochnia[2], Stanisław Dzimira[4], , Dorota Szumny[1,3] Adam Szeląg[1] Antoni Szumny[5]

1 Department of Pharmacology, Wroclaw Medical University, Department of Pharmacology, ul. Mikulicza-Radeckiego 2, 50-345 Wroclaw, Poland, wojciech.dziewiszek@umed.wroc.pl
2 Department and Clinic of Otolaryngology, Head and Neck Surgery, Faculty of Medicine, Faculty of Postgraduate Medical Training, Wroclaw Medical University, Poland. marek.bochnia@umed.wroc.pl
3 Ophthalmology Clinic, Uniwersytecki Szpital Kliniczny, Borowska 213, 50-556 Wrocław, Poland, dorotaszumny@wp.pl
4 Department of Pathology, Wroclaw University of Environmemntal and Life Sciences, C.K. Norwida 31, 50-375 Wroclaw, stanislaw.dzimira@upwr.edu.pl
5 Department of Chemistry, Wroclaw University of Environmental and Life Sciences, Norwida 25, 50-375 Wroclaw, Poland; antoni.szumny@upwr.edu.pl
* Correspondence: dorotaszumny@wp.pl

Abstract:

Deer antler is the only mammalian organ that can fully grow back once lost from its pedicle. Antler regeneration is a stem cell-based process.Therefore, antlers probably offer the most pertinent model for studying organ regeneration in mammals. Evaluation of the effect of deer antler stem cells on healing of superficial and deep rabbit corneal wounds. 36 New Zealeand White rabbits were used in this study in superficial and deep denaturation models, corneal erosion was made with *n*-heptanol placed on the cornea for 30- and 90 seconds. Antler stem cells in drop formulation with hyaluronate was used. As a control was administered sodium hyaluronate in the superficial model and protein-free calf blood dialysate (Solcoseryl) in the deep model. In superficial corneal damage, a reduction in the area of damaged cornea was observed from day 3 of the experiment to an adequate level: 45% in the test group and 52% in the control group relative to the baseline damage (100%). Between days 3 and 7, on average, a smaller lesion area was observed in the group receiving antler stem cells. The use of antler stem cells has resulted in a marked improvement in cornea clarity. According to the 5-point scale of corneal opacity evaluation, where 1 is completely clear and 5 is completely opaque, the first statistically significant changes were observed after 4 weeks of treatment: 3.0 in the study group, 4.1 control with Solcoseryl and 4.4 in the control group. After 9 weeks, these values were, respectively: 2.5, 3.8 and 4.1. The present preliminary study shows the promising results of antlerogenic stem cells of Cervus elaphus topically application for the treatment of corneal injury. A deeper understanding of the developmental mechanisms involved in antler renewal can be useful for controlling regeneration cornea processes.

Keywords: *Cornea, stem cells, corneal burn, Cervus elaphus, antler*

Academic Editor: Firstname Lastname
Received: date
Accepted: date
Published: date

Publisher's Note: MDPI stays neutral with regard to jurisdictional claims in published maps and institutional affiliations.

Copyright: © 2021 by the authors. Submitted for possible open access publication under the terms and conditions of the Creative Commons Attribution (CC BY) license (http://creativecommons.org/licenses/by/4.0/).

1. Introduction

Deer antler is the only mammalian organ that can fully grow back once lost from its pedicle. Therefore, antlers probably offer the most pertinent model for studying organ regeneration in mammals. Antler regeneration is a stem cell-based process and antler stem cells reside in the periosteum of the pedicle, the permanent bony protuberance, from which antler regeneration occurs[1].

The pedicle periosteum (PP) cells are direct derivatives of cellsresident in the antlerogenic periosteum (AP), a tissue that exists in prepubertal deer calves and can induce

ectopic antler formation when transplanted elsewhere on the deer body. Both AP and PP cells express key embryonic stem cell markers and can be induced to differentiate into multiple cell lineages in vitro, and, therefore, they are termed antler stem cells, and antler regeneration is a stem cell-based epimorphic regeneration [2].

The cornea is a highly specialized transparent tissue, which is an important refractive center. It is essential for normal vision and any disturbances of the cornea usually lead to a decrease in visual acuity or even loss of vision. Being the most anterior part of the eyeball, it is also more vulnerable than other structures to trauma from impact, infection, or surgery.

The cornea is made up of several layers: the anterior epithelium, the anterior limiting lamina, the so-called Bowman's membrane, the dermis or stroma, the posterior limiting lamina, Descemet's membrane, and the posterior epithelium, the endothelium[3]. Depending on the extent of corneal damage and which layers of the cornea were damaged in the repair process, there is an inflammatory reaction with or without fibrosis, which usually leads to opacity and scar formation, followed by permanent visual impairment.

However, by far the most common result of various corneal injuries is superficial corneal erosion, which does not result in scar formation after healing. It involves only the corneal epithelium, very well innervated, whose damage causes the patient severe pain, as well as tearing, conjunctival redness, swelling, and great discomfort. When the erosion is large, multiple corneal erosions are present, or the patient is taking medication to inhibit re-epithelialization, the recovery process is prolonged, resulting in longer pain for the patient.

The way to rebuild a damaged cornea is to heal or replace it. Initially, a variety of therapeutic substances are used, but if these are ineffective, surgical methods are used.

The introduction of substances that accelerate corneal re-epithelialization could significantly help patients by relieving the usually very severe pain. One of the directions of current research on substances accelerating wound healing is stem cells, whose potential therapeutic application is also being tested in ophthalmology.

One of the most serious eye surface injuries is a chemical corneal burn. It can cause permanent loss of transparency, ingrowth of new abnormal vessels, secondary glaucoma, and lead to blindness.

This study aimed to evaluate the effect of stem cells from red deer antlers (ASC, antler stem cells) on corneal wound healing after superficial and deep damage following exposure to *n*-heptanol.

2. Materials and Methods

This study was approved by the Animal Research Ethics Committee in Wroclaw, Poland. (Nr 7/2011 from 16.03.2011)

Preparation of stem cells:

The formulation used for the experiment is made of antlerogenic stem cells of Cervus elaphus cultured under standard conditions [4]. After homogenization of 500000 cells, we received 1mL of drops.

An MIC-1 stem cell line was derived from growing red deer antlers. The culture was conducted in an incubator under standard conditions in 175 mL bottles in culture medium - MEM from Cambrex with 10% fetal bovine serum, 100 U.I/mL penicillin and 0.1 mg /mL streptomycin for a 14-day culture cycle. After obtaining a complete monolayer, cells were detached from the bottom of the culture bottle using 0.05% trypsin with 0.02% ethylenediaminetetraacetic acid (EDTA) and transferred to centrifuge tubes. Cells were then washed twice in PBS and centrifuged. The cell line was resuspended in 0.9% sodium

chloride at a rate of 1 billion cells per 50 mL of fluid. The homogeneous suspension was cooled in a water-cooled homogenization chamber to approximately 4 °C. In a continuous water-cooled steel chamber, cell disruption was performed using 20 kHz ultrasound over 30 seconds. The solution was titrated in biological units - the extract obtained from 1 million cells was taken as 1 unit. Eye drops were made on saline medium at a concentration of 1 unit per 1 mL and gel for the eye on a prepared substrate: 2 mg carbomer and excipients: cettrimide, sodium hydroxide, sorbitol, water for injection contained in 1 g of gel, 1 biological unit of homogenate.

Animals

36 New Zealand White rabbits, both sexes, weight 2-3 kg, were used in this study. All animals were housed in individual cages with unrestricted access to water and food, on a 12 h light:12 h dark cycle. Prior to the experiment, the eyes of all rabbits were examined to exclude existing abnormalities of the cornea, conjunctiva, and other anterior ocular structures (anterior chamber, iris). For this purpose, a fluorescein test (evaluation of a cobalt filter of the anterior segment after prior administration of a 2% fluorescein solution into the conjunctival sac) and slit-lamp examination were performed.

Superficial denaturation animal model

One eye of each animal was treated, and the fellow eye served as the control. Erosion of the corneal epithelium was performed in both eyes: after local anesthesia, Sol. Alcaine (chlorowodorek proxymetakainy 5mg/mL , Alcon), a 3 mm diameter disc (Whatmana nr 1 tissue paper) soaked in pure *n*-heptanol (Sigma-Aldrich) was placed on the cornea, and allowed to stand for 30 seconds, according to approach 5 and 6. After removal, the eye was washed with an isotonic aqueous solution of 0.9% NaCl.

Deep denaturation animal model

One eye of each animal was treated, and the fellow eye served as the control. Erosion of the corneal epithelium was performed in both eyes: after local anesthesia, Sol. Alcaine (proxymetacaine hydrochloride, 5mg/mL , Alcon), a 3 mm diameter disc (Whatman nr 1 tissue paper) soaked in *n*-heptanol (Sigma-Aldrich) was placed on the cornea, and allowed to stand for 90 seconds. After removal, the eye was washed with an isotonic aqueous solution of 0.9% NaCl, and the experiment approach was based on the protocol proposed by Chung, [5].

Epithelial wound healing

To assess the rate of corneal wound healing, rabbit eyes were stained with 2% fluorescein solution and examined using a slit lamp, fluorescein staining and photography of the cornea with an interval of 10 h between the generation of corneal erosion and the beginning of measurements. This time corresponds to the lag phase of corneal wound healing observed in vivo.

During the experiment, rabbits received the homogenate in the drops in the superficial denaturation model, in gel in the deep denaturation model, in each case one drop to the right eye, 3 times a day to the last day. The vehicle was administered to the left eye, which is the control with the same schedule and amount. As a positive control for the deep denaturation animal model, protein-free calf blood dialysis was administered (Solcoseryl, 4.15 mg/g, MEDA, Sweden). Eyes were examined after 10, 24, 48, and 72 hours. In case of incomplete healing of corneal wounds within 72 hours, examinations were continued every 24 hours until complete epithelial recovery. The corneal injury and

its rate of healing in the study group compared to controls, as well as the condition of the rest of the anterior segment of the eyeball, were evaluated. During each examination, a photograph of the corneal surface was taken, and the damaged area was measured. The decrease in wound area over time was evaluated. The experiment was terminated when 100% closure of each corneal wound was achieved. In the deep denaturation model group, the study was continued until week 9, examining the effect of the administered substances on the presence of corneal opacity.

Histologic studies

Each cornea was isolated post mortem for histological examination. Tissue sections were fixed in 7 % buffered formalin solution, embedded in paraffin and cut into 4 μm thick slices and stained with hematoxylin and eosin method. Specimens were blindly examined in the Olympus CX-41 light microscope coupled with a UP-20 photographic camera by an experienced pathomorphologist. Anterior corneal epithelial thickness measurements were performed using Cell Sens Dimension software.

Methodology for assessing the extent of eye damage.

The eye was photographed with a Nikon D80 camera with a Vivitar 100mm f 3.5 macro lens at a scale of 1:1 from a fixed distance from the eye. The image was edited in GIimp 2 software. The diameter of the lesion was measured using a tape measure and the opacity of the damaged cornea was assessed. Assessments were made weekly from day 2 of the experiment for 9 weeks. The surface of the damaged cornea was measured in pixels, analyzing the extent of damage using the computer program Adobe Photoshop CS4 Extended.

The authors introduced a corneal damage rating scale after the epithelialization period was complete, which was used to assess deep damage:

1: Completely transparent; 2: Completely slightly hazy; 3. Completely slightly hazy, containing complete opacity covering less than 50% of the total area of opacity; 4. Completely slightly hazy, containing total opacities covering more than 50% of the total area of opacity; 5. A total of opaques

Statistical analysis

All data are presented as mean. Student's t-test (unpaired) was used as indicated in the text to compare continuous variables. The statistical significance level was set at $P<0.05$. Statistical analysis was performed using Dell Statistica version 13.

3. Results

Superficial damage

The results in a superficial damage group were averaged - assessing the reduction in the surface of the wound over time. Corneal healing treated by the investigated preparations followed on the second day and on the 3rd day in the control group. No opacity formation was observed in any cornea after a period of epithelial regeneration. In the study, the surface area of the epithelium of the damaged cornea was measured, stained with fluorescein after illumination with a UV lamp operating at 485 nm. After the first day of the preparation application, no differences between the groups were observed and the measured damage was close to the initial value. However, already 48 hours after the eye drops, a decrease in the surface area of the damaged cornea was observed to the

appropriate level: 45% in the ASC group and 52% in the control group compared to the initial damage. The drop in the surface area lasted until the end of the experiment, i.e., until day 7, when complete healing of the epithelium was observed. Between the 3rd and 7th day, an average smaller surface area of the lesion was observed in the group receiving ASC (Fig. 1).

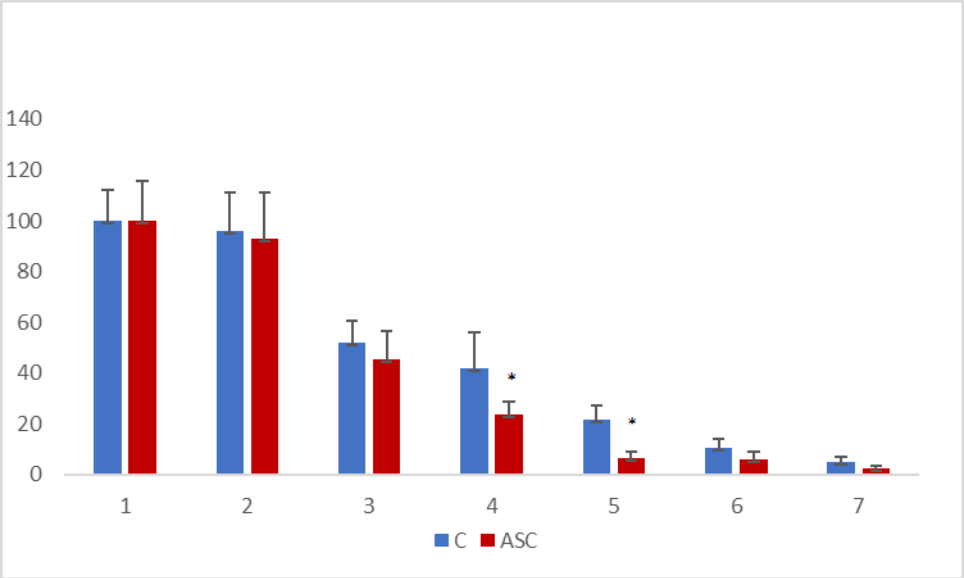

Figure 1. The surface area of the damaged cornea according to time staining with fluorescein. The field of primary *n*-heptanol damage was assumed to be 100%. Red: ASC; blue: control.

Acceleration of corneal healing can occur after administration of low-molecular organic compounds. Toshida *et al.* [6]. High solution of retinol palmitate to treat corneal damage with *n*-heptanol. However, effective treatment required eye drops 6 times a day at a dose of over 1000 mU/mL . At the same time, complete healing of the cornea was observed on the 12th day after the damage.

Burgalassi *et al.* [7]. showed that a polysaccharide fraction isolated from tamarind (*Tamarindus indica* L.) seeds slightly, in but significantly increased the wound healing rate caused by surface alcohol damage.

Deep damage

In the case of heptanol-induced corneal opacity, the use of ASC has resulted in a marked improvement in clarity. According to the assumed 5-stage corneal opacity score scale, where 1 - completely clear, 5 - completely opaque, the first statistically significant changes were observed already after 4 weeks of administration (Fig. 2). The translucency compared to the initial value increased by about two units with an average value of 3.06. It should be noted that the improvement in translucency was observed after the second week of administration of ACS, but these changes were not statistically significant. The use of eye drops with Solcoseryl after the fourth week of administration brought only a statistically insignificant improvement (to about 2.5). The observed regeneration of ASC was much more effective compared to the Solcoseryl preparation. In his case, a reduction

in corneal damage was observed only after eight weeks of application, and the final value of corneal haze was as high as 3.8.

The observed ACS regenerative activity is similar to that of amniotic membrane mesenchymal bone marrow stem cells. For alkali injury (0.5 N NaOH) in rats, Jiang *et al.* observed an improvement in corneal clarity only in the 10th week of use of the examined maternal cells. This improvement was approximately 1.5 points on a comparative scale for corneal opacity [8].

significant).

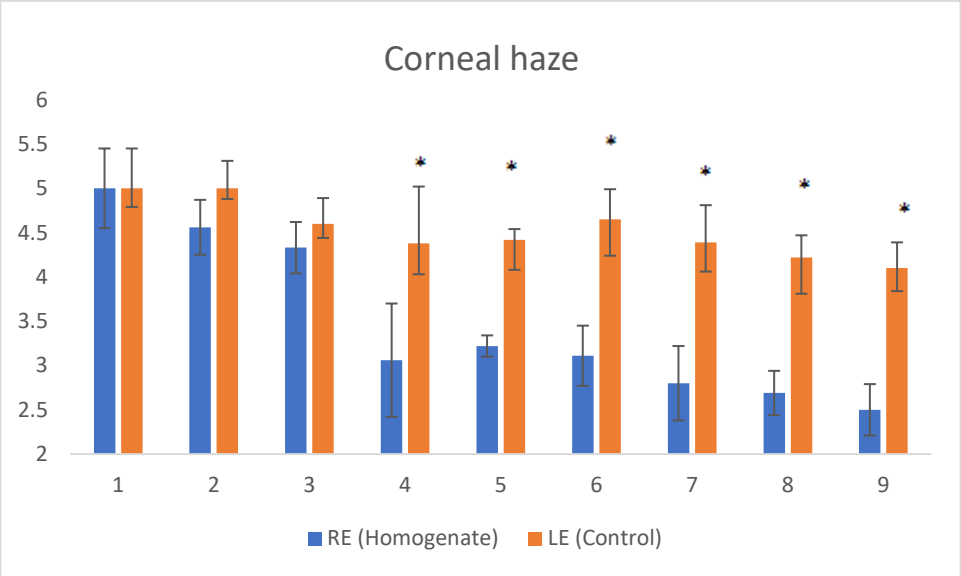

Figure 2. Corneal damage scores from the start of the experiment to week 9, on a 5-point scale (1 - cornea completely clear, 5 - cornea completely opaque) in the homogenate-treated group compared to the control. Observations were made at 9 weeks (x-axis). RE – right eye, LE – left eye. *- statistically signifficant

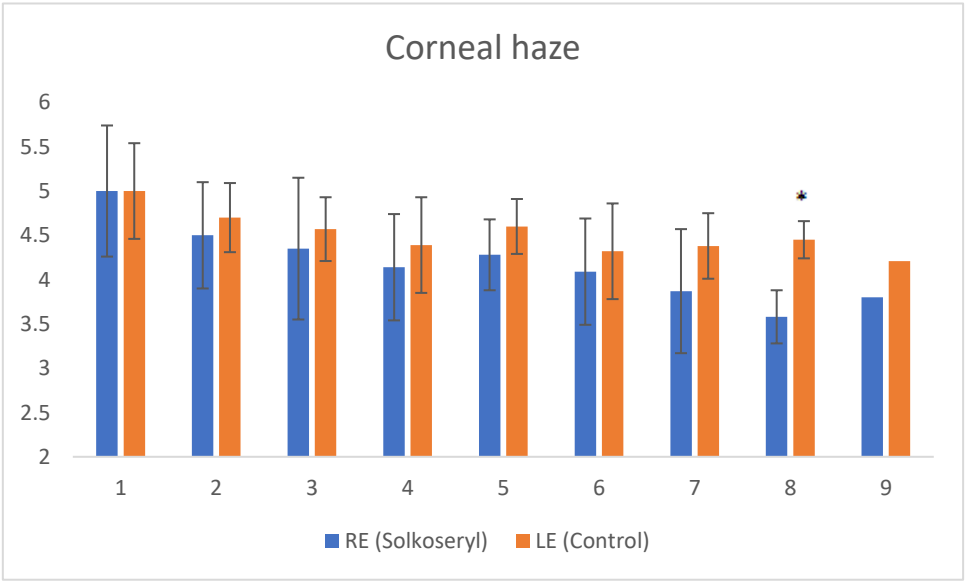

Figure 3

Corneal damage scores from the start of the experiment to week 9, on a five-point scale (1 - cornea completely clear, 5 - cornea completely opaque) in the Solcoseryl-treated group compared to controls. Observations were made at 9 weeks (x-axis). RE – right eye, LE – left eye. *- statistically significant

Histological findings and epidermal thickness

For superficial corneal epithelial damage, histopathological examination on day 7 of the experiment showed no difference between the two study groups. The application of both ASC and vehicle had an identical effect on the corneal epithelial pattern. Only trace damage to the surface of the anterior corneal epithelium was noted in the microscopic image. This study confirms the healing rate result shown in Fig. 1. This effect is consistent with the results presented by Li *et al.*, [2] where the healing of the corneal endothelial cells after alcali burn was studied.

In the deep denaturation model group, the changes were more diverse: significant epithelial damage, corneal stromal dilation, or anterior epithelial detachment was observed. After 9 weeks of the experiment (deep denaturation model), both the homogenate and Solcoseryl groups showed more anterior corneal epithelial thickening compared with the control group, and the difference was statistically significant (Table 1). The average epithelial thickness was 20% higher with ASC and over 42% higher with Solcoseryl compared to the control group. The phenomenon of corneal changing after chemical (NaOH) burn was described by Reim *et al.* [9]

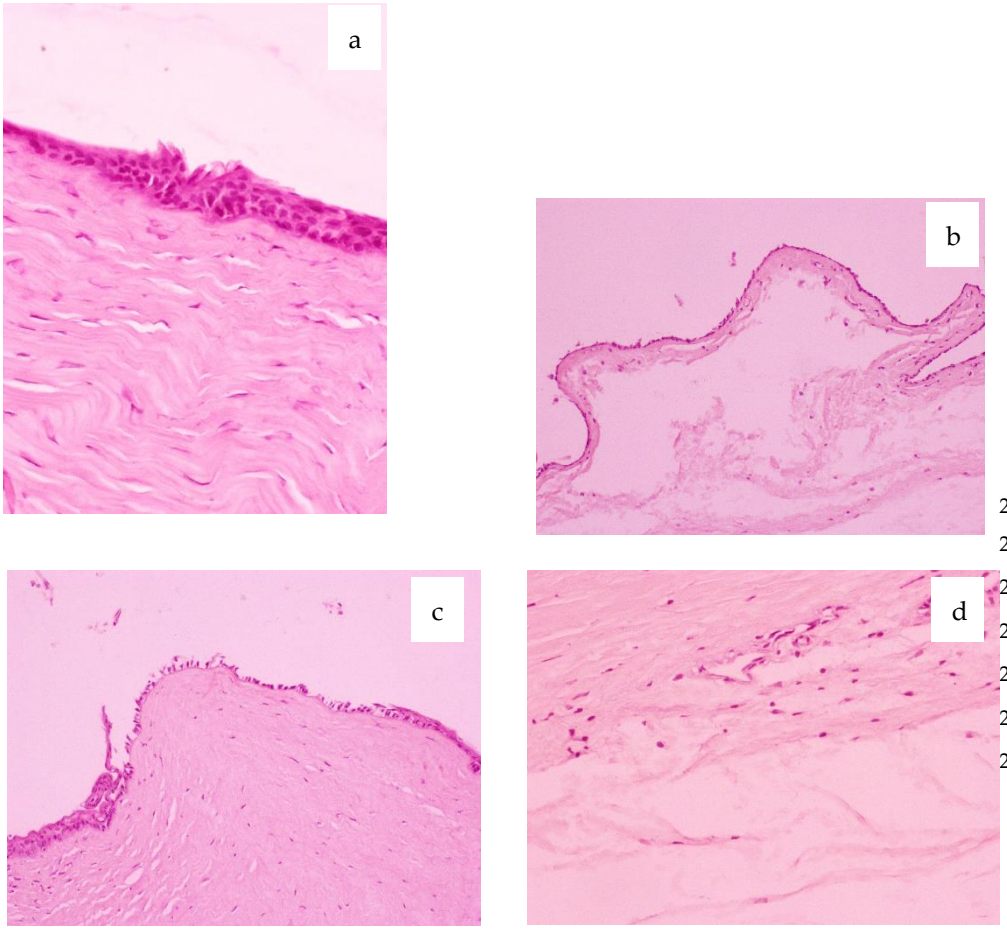

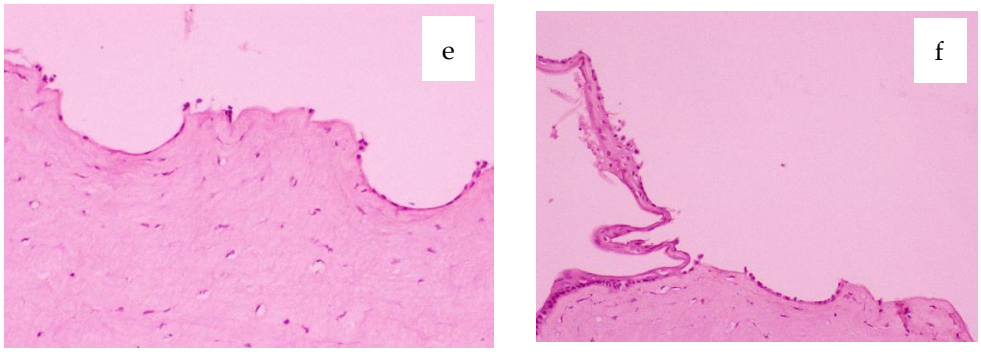

Figure 4,
Microscopic examination showed in the preparation of the superficial corneal lesion model no or only slight damage to the corneal anterior epithelium (a). The deep corneal lesion preparations showed significant epithelial damage, corneal stromal dilatation, epithelial thinning, and more severe changes with anterior epithelial detachment (b-f).

4. Discussion

One of the most serious corneal injuries is burns. Chemical injury of the eye may produce extensive damage to the ocular surface epithelium, cornea, and anterior segment, resulting in permanent visual impairment. Immediately following chemical injury, it is important to estimate and clinically grade the severity of limbal stem cell injury and intraocular penetration of the noxious agent. Immediate therapy is directed toward prompt irrigation and removal of any remaining reservoir of chemical contact with the eye. Initial medical therapy is directed at promoting re-epithelialization and transdifferentiation of the ocular surface, augmenting corneal repair by supporting keratocyte collagen production and minimizing ulceration related to collagenase activity, and controlling inflammation [10].

Acute phase treatment includes a broad spectrum topical antibiotic, cycloplegic, and antiglaucoma therapy [11]. Oral treatment with doxycycline was found to be very effective in preventing corneal angiogenesis and inflammation of alkali-burned corneas [12].

Very good experiences in oxidative disorder management have been achieved with tear supplements, particularly based on hyaluronic acid, topically administered corticosteroids, and prophylactic antibiotic use. Chemically modified and cross-linked hyaluronan gels improved corneal wound healing after alkali injury in rabbits. The wound closure rate and thickness of the corneal epithelium in eyes treated with hyaluronan gel were significantly greater than in untreated injured eyes.

Sekundo *et al.* examined the effect of antioxidants (allopurinol and acetylcysteine) and corticosteroids (prednisolone acetate) in eye drops in the healing of corneal alkali burns[13]. These drugs were effective particularly in the early treatment of experimental

corneal burns. Saud *et al.* described a favorable effect of subconjunctival injection of triamcinolone after corneal alkali burns in rabbits [14]. Triamcinolone was very effective for the treatment of acute ocular burn because it reduced the corneal inflammatory process, opacity, and vascularization. It was also checked in transdifferentiated bone marrow or hair follicle stem cells [15]. One therapeutic option is to use drops from the patient's own serum. Human serum contains a physiological plethora of bioactive elements naturally released by activated platelets, which might have a significant effect on the regeneration of corneal layers by stimulating cell growth [16]. Calf blood dialysate is also used to accelerate wound healing of the skin, mucosa and cornea (Solcoseryl) [17].

The effect confirming the regenerative properties of the substance is the acceleration of the growth rate of the corneal epithelium compared to the control group. The turnedover of epithelium cells could approximate from 7 to 10 days. Although multiplication and acquisition of human-derived maternal cells is possible and has good therapeutic results, it is expensive and requires constant cooperation with the cell culture laboratory. Standardization of such obtained cells is also problematic. An additional obstacle of the above-mentioned cellular therapies is the necessity of many days of hospitalization of the treated patient. These problems are solved by administering standardized stem cells in eye drops grown from deer antlers. Multiplied laboratory stem cells are used to treat corneal damage. They may come from a healthy eye, the same patient, the same donor, as well as from the oral mucosa. Bains *et al.* [18]. Proven usability of bulge-derived, immature dental pulp, umbilical cord, induced pluripotent, mesenchymal or embryonic stem cells in successful treatment of corneal lesions. In 2020, Qiu *et al.* adipose tissue-derived stem cells were used to treat model rabbit n-heptanol corneal injury [19]. They proved that Ocular surface reconstruction can be improved by using applied stem cells. Corneal wounds can be angled by using maternal cells from the intact eye. Gimeo *et al.*, applied autologous limbal epithelial cell transplantation improved after corneal injury with alkaline [20]. Long-term observation of the effects of limbal stem cell treatment on corneal damage with heptanol showed that the corneal healing effect persisted even after one year [21]. In the conducted experiment, we noticed a statistically significant increase in the mean thickness of the anterior corneal epithelium for the group treated with the homogenate of deer antler stem cells. For the homogenate group, it was the mean value of 19.2, compared to the value of 15.2 in the control group. It should also be emphasized here that there were no statistically significant differences in epithelial thickness between the homogenate and solcoseryl groups. One idea for a new therapy is trying to use stem cells from the antlers of the deer Cervus elaphus. Antlers are the only mammalian organ that can fully regenerate [1].

The renewal of the corneal and regeneration is mediated by the limbus stem cells that are located in the thick zone between the bulbar conjunctiva and the cornea [22]. Recent research has proven that the regenerative action of deer stem cells is connected with pleiotrophin as a multifunctional growth factor [23]. Wang et. al. proved that deer antler cells belong to a novel type of cells that sustain full regeneration of mammalian organs. [24].

There are the apparent lack of any specific 'antlerogenic molecular mechanisms' suggesting that the secret of deers' ability to regenerate antlers lies in the particular cues to which multipotential progenitor/stem cells in an antler's 'regeneration territory' are exposed. This in turn suggests that with appropriate manipulation of the environment, pluripotential cells in other adult mammalian tissues could be stimulated to increase the healing capacity of organs, even if not to regenerate them completely. The benefits of increasing individuals' own capacity for regeneration and repair are self-evident [25].

Comparisons between the healing process of the stumps of an amputated mouse limb and early regeneration of antlers suggest that the stump of a mouse limb cannot regenerate because of the limited potential of periosteal cells in long bones to proliferate [2].

Healing of the casting wound in deers typically involves no or only minor scarring, making antlers interesting subjects for researchers attempting to reduce scar formation during wound healing in humans, especially in the cornea. Additionally, despite the enormous growth rate, the antlers appear to be resistant to malignant transformation, which furthermore offers research opportunities for cancer biology[26].

A greater understanding of the mechanisms that regulate the regeneration of antlers may provide a valuable insight to aid the field of regenerative medicine.

5. Conclusions

In conclusion, the present preliminary study shows the promising results of antlerogenic stem cells of Cervus elaphus topically application for the treatment of corneal injury in New Zealand rabbit model. In case of superficial corneal damage by *n*-heptanol, a reduction in the area of damaged cornea was observed from day 3, in comparison with hyaluronic acid composition. Corneal haze was reduced significantly effectively when ASC was applied, in comparison with solcoseryl. A deeper understanding of the developmental mechanisms involved in antler renewal can be useful for controlling regeneration cornea processes.

Author Contributions: WD and MB: Conceptualization, investigation DSz: conceptualization, writing—review and editing investigation methodology data curation; SD: histological anlysis ASzel:coordination; ASzu: writing—review and editing data curation.

Funding: none

Institutional Review Board Statement: All experimental procedures used in this study were approved by the II Local Ethics Committee in Wroclaw, Poland (permission No 7/2011).

Conflicts of Interest: The authors declare no conflict of interest.

References

1. Ba, H.; Wang, D.; Li, C. MicroRNA profiling of antler stem cells in potentiated and dormant states and their potential roles in antler regeneration. *Molecular Genetics and Genomics* **2016**, *291*, 943-955.
2. Lee, H.S.; Lee, J.H.; Kim, C.E.; Yang, J.W. Anti-neovascular effect of chondrocyte-derived extracellular matrix on corneal alkaline burns in rabbits. *Graefe's archive for clinical and experimental ophthalmology = Albrecht von Graefes Archiv fur klinische und experimentelle Ophthalmologie* **2014**, *252*, 951-961, doi:10.1007/s00417-014-2633-3.
3. Lwigale, P.Y. Corneal development: different cells from a common progenitor. *Progress in molecular biology and translational science* **2015**, *134*, 43-59.
4. Cegielski, M.; Dziewiszek, W.; Zabel, M.; Dzięgiel, P.; Iżycki, D.; Zatoński, M.; Bochnia, M. Experimental application of xenogenous antlerogenic cells in replacement of auricular cartilage in rabbits. *Xenotransplantation* **2008**, *15*, 374-383.
5. Chung, J.-H.; Kim, W.-K.; Lee, J.-S.; Pae, Y.-S.; Kim, H.-J. Effect of topical Na-hyaluronan on hemidesmosome formation in n-heptanol-induced corneal injury. *Ophthalmic research* **1998**, *30*, 96-100.
6. Toshida, H.; Odaka, A.; Koike, D.; Murakami, A. Effect of retinol palmitate eye drops on experimental keratoconjunctival epithelial damage induced by n-heptanol in rabbit. *Current eye research* **2008**, *33*, 13-18.

7. Burgalassi, S.; Raimondi, L.; Pirisino, R.; Banchelli, G.; Boldrini, E.; Saettone, M.F. Effect of xyloglucan (tamarind seed polysaccharide) on conjunctival cell adhesion to laminin and on corneal epithelium wound healing. *European Journal of Ophthalmology* **2000**, *10*, 71-76.
8. Jiang, T.-S.; Cai, L.; Ji, W.-Y.; Hui, Y.-N.; Wang, Y.-S.; Hu, D.; Zhu, J. Reconstruction of the corneal epithelium with induced marrow mesenchymal stem cells in rats. *Molecular vision* **2010**, *16*, 1304.
9. Reim, M.; Bahrke, C.; Kuckelkorn, R.; Kuwert, T. Investigation of enzyme activities in severe burns of the anterior eye segment. *Graefe's archive for clinical and experimental ophthalmology* **1993**, *231*, 308-312.
10. Wagoner, M.D. Chemical injuries of the eye: current concepts in pathophysiology and therapy. *Survey of ophthalmology* **1997**, *41*, 275-313.
11. Singh, P.; Tyagi, M.; Kumar, Y.; Gupta, K.; Sharma, P. Ocular chemical injuries and their management. *Oman journal of ophthalmology* **2013**, *6*, 83.
12. Cejkova, J.; Trosan, P.; Cejka, C.; Lencova, A.; Zajicova, A.; Javorkova, E.; Kubinova, S.; Sykova, E.; Holan, V. Suppression of alkali-induced oxidative injury in the cornea by mesenchymal stem cells growing on nanofiber scaffolds and transferred onto the damaged corneal surface. *Exp Eye Res* **2013**, *116*, 312-323, doi:10.1016/j.exer.2013.10.002.
13. Sekundo, W.; Augustin, A.; Strempel, I. Topical allopurinol or corticosteroids and acetylcysteine in the early treatment of experimental corneal alkali burns: a pilot study. *European journal of ophthalmology* **2002**, *12*, 366-372.
14. Saud, E.E.; Moraes Jr, H.V.; Marculino, L.G.; Gomes, J.A.P.; Allodi, S.; Miguel, N.C. Clinical and histopathological outcomes of subconjunctival triamcinolone injection for the treatment of acute ocular alkali burn in rabbits. *Cornea* **2012**, *31*, 181-187.
15. Eberwein, P.; Reinhard, T. Current and future therapeutic options in limbal stem cell insufficiency. *Klinische Monatsblatter fur Augenheilkunde* **2012**, *229*, 1178-1184.
16. De Pascale, M.R.; Lanza, M.; Sommese, L.; Napoli, C. Human serum eye drops in eye alterations: an insight and a critical analysis. *Journal of ophthalmology* **2015**, *2015*.
17. Konturek, S.J.; Drozdowicz, D.; Pytko-Polonczyk, J.; Brzozowski, T.; Bielanski, W. Solcoseryl in prevention of stress-induced gastric lesions and healing of chronic ulcers. *Journal of physiology and pharmacology : an official journal of the Polish Physiological Society* **1991**, *42*, 73-84.
18. Bains, K.K.; Fukuoka, H.; Hammond, G.M.; Sotozono, C.; Quantock, A.J. Recovering vision in corneal epithelial stem cell deficient eyes. *Contact Lens and Anterior Eye* **2019**, *42*, 350-358.
19. Qiu, T.; Cui, L.; Xu, J.-J.; Hong, J.-X.; Xiang, J. Reconstruction of the ocular surface by autologous transplantation of rabbit adipose tissue-derived stem cells on amniotic membrane. *Annals of Translational Medicine* **2020**, *8*.
20. Gimeno, F.L.; Lavigne, V.; Gatto, S.; Croxatto, J.O.; Correa, L.; Gallo, J.E. Advances in corneal stem-cell transplantation in rabbits with severe ocular alkali burns. *Journal of Cataract & Refractive Surgery* **2007**, *33*, 1958-1965.
21. Ti, S.-E.; Anderson, D.; Touhami, A.; Kim, C.; Tseng, S.C. Factors affecting outcome following transplantation of ex vivo expanded limbal epithelium on amniotic membrane for total limbal deficiency in rabbits. *Investigative ophthalmology & visual science* **2002**, *43*, 2584-2592.
22. Pellegrini, G.; De Luca, M. Eyes on the prize: limbal stem cells and corneal restoration. *Cell Stem Cell* **2014**, *15*, 121-122.
23. Dong, Z.; Li, C.; Coates, D. PTN− PTPRZ signalling is involved in deer antler stem cell regulation during tissue regeneration. *Journal of Cellular Physiology* **2020**.
24. Wang, D.; Berg, D.; Ba, H.; Sun, H.; Wang, Z.; Li, C. Deer antler stem cells are a novel type of cells that sustain full regeneration of a mammalian organ—deer antler. *Cell death & disease* **2019**, *10*, 1-13.
25. Price, J.; Faucheux, C.; Allen, S. Deer antlers as a model of Mammalian regeneration. *Current topics in developmental biology* **2005**, *67*, 1-48.

26. Kierdorf, U.; Kierdorf, H. Deer antlers–a model of mammalian appendage regeneration: an extensive review. *Gerontology* **2011**, *57*, 53-65.